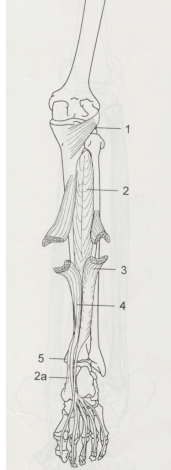


DEEP POSTERIOR LEG MUSCLES

POPLITEUS
TIBIALIS POSTERIOR
FLEXOR HALLUCIS LONGUS
FLEXOR DIGITORUM LONGUS



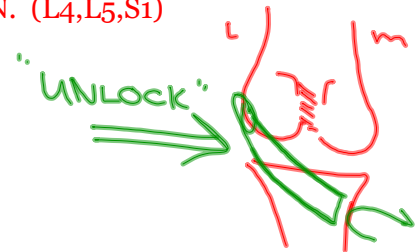
POPLITEUS

O: LATERAL SURFACE OF LATERAL CONDYLE OF FEMUR

I: UPPER PART OF POSTERIOR SURFACE OF TIBIA

A: ROTATES LEG MEDIALY, FLEXES LEG

N: TIBIAL N. (L4,L5,S1)



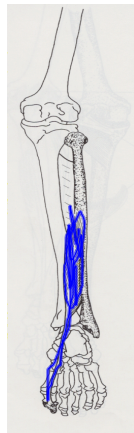
FLEXOR HALLUCIS LONGUS

O: LOWER 2/3 OF POSTERIOR SURFACE OF FIBULA, POSTERIOR INTRERMUSCULAR SEPTUM, INTEROSSEOUS MEMBRANE

I: BASE OF DISTAL PHALANX OF GREAT TOE

A: FLEXES DISTAL PHALANX OF GREAT TOE, ASSIST PLANTARFLEXION, INVERT FOOT

N: TIBIAL N. (L4,L5,S1)



FLEXOR DIGITORUM LONGUS

O: MEDIAL PART OF POSTERIOR SURFACE OF TIBIA

I: BASES OF DISTAL PHALANGES OF 2ND, 3RD, 4TH AND 5TH TOES

A: FLEXES DISTAL PHALANGES OF LATERAL FOUR TOES, ASSIST PLANTARFLEXION, INVERT FOOT

N: TIBIAL N. (L5,S1)



TIBIALIS POSTERIOR

O: LATERAL PART OF POSTERIOR SURFACE OF TIBIA, INTEROSSEOUS MEMBRANE, POSTERIOR SURFACE OF FIBULA

I: TUBEROSITY OF NAVICULAR BONE, CUBOID, CUNEIFORMS, 2ND, 3RD AND 4TH METATARSALS

A: PLANTAR FLEXES AND INVERTS FOOT

N: TIBIAL N. (L5,S1)

