

ANTERIOR L.L MUSCLES

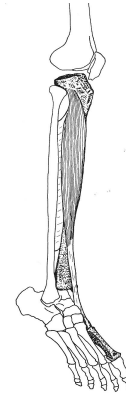
TIBIALIS ANTERIOR:

**O: LATERAL CONDYLE OF TIBIA,
UPPER HALF OF LATERAL
SURFACE OF TIBIA,
INTEROSSEOUS MEMB.**

**I: MEDIAL SIDE AND PLANTAR
SURFACE OF MEDIAL
CUNEIFORM, BASE OF 1ST MT**

**A: DORSIFLEX FOOT AT ANKLE,
INVERTS ANKLE**

**N: DEEP PERONEAL NERVE (L4,
L5, S1)**



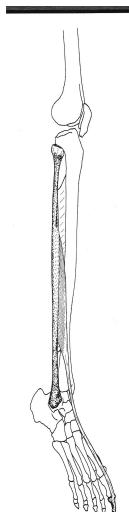
EXTENSOR HALLUCIS LONGUS:

**O: MIDDLE HALF ANTERIOR
SURFACE OF FIBULA AND
INTEROSSEOUS MEM.**

**I: BASE OF DISTAL PHALANX OF
GREAT TOE**

**A: EXTENDS, HYPEREXT GREAT
TOE, DORSIFLEX AND INVERT
FOOT**

N: DEEP PERONEAL N. (L4,L5,S1)



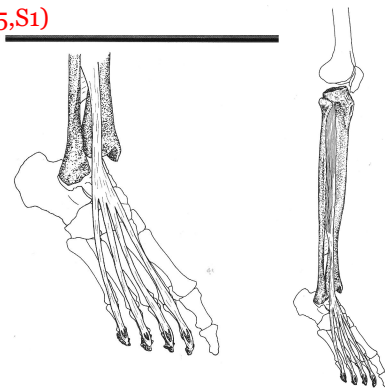
EXTENSOR DIGITORUM LONGUS:

**O: UPPER 2/3 OF ANTERIOR
SURFACE OF FIBULA,
INTEROSSEOUS MEMB., LAT.
CONDYLE OF TIBIA**

**I: ALONG DISTAL SURFACE OF
FOUR LATERAL TOES, BASES OF
MIDDLE AND DISTAL PHALANGES**

**A: EXTENDS TOES, DORSIFLEX
FOOT AT ANKLE, EVERTS**

**N: DEEP PERONEAL NERVE
(L4,L5,S1)**



PERONEUS TERTIUS:

O: LOWER 1/3 OF ANT. SURFACE OF FIBULA AND INTEROSSEOUS MEM

I: DORSAL SURFACE OF BASE OF 5TH MT

A: DORSIFLEXES AND EVERTS FOOT

N: DEEP PERONEAL N. (L4,L5,S1)

